

ARACHNOIDITIS BASIC HANDBOOK FOR PRACTITIONERS, PATIENTS & FAMILIES

**Written by Forest Tennant M.D., Dr. P.H.
with assistance from Ingrid Hollis and Lynn Ashcraft**


This handbook contains 18 separate bulletins which provide the basic information on arachnoiditis and its treatment. Individual bulletins are updated as new information comes available.

Revised June, 2018

***Published by the Tennant Foundation
Arachnoiditis Education Project
334 S. Glendora Ave., West Covina, CA 91790-3043
Phone: 626-919-7476 Fax: 626-919-7497
E-mail: veractinc@msn.com
www.arachnoiditishope.com***

TABLE OF CONTENTS

1. EXPLANATIONS & DEFINITIONS
2. ADHESIVE ARACHNOIDITIS – NO LONGER RARE
3. AA INVOLVES HANGING LUMBAR NERVE ROOTS
4. TWO WAYS THAT AA MAY DEVELOP
5. COMMON SYMPTOMS OF ADHESIVE ARACHNOIDITIS
6. DIAGNOSIS OF LUMBAR AA
7. DIAGNOSIS OF CERVICAL/NECK ARACHNOIDITIS
8. SCREENING FOR LUMBAR AA
9. CONSEQUENCES AND COMPLICATIONS OF AA
10. OUTCOMES OF UNTREATED AA
11. TREATMENT – 4 BASIC COMPONENTS
12. CHRONIC SPINAL FLUID LEAKAGE
13. MAJOR GOAL OF TREATMENT: STOP THE PROGRESSION
14. THE EARLIER THE TREATMENT—THE BETTER THE OUTCOME
15. WALKING, LIFTING, AND BRACING
16. IMPROVING YOUR SPINAL FLUID FLOW
17. STRETCHING EXERCISES: STAY OUT OF A WHEELCHAIR
18. THREE (3) KINDS OF PAIN YOU MUST TACKLE



EXPLANATIONS AND DEFINITIONS, YOU MUST KNOW

SPINAL CANAL: The spinal canal consists of 4 components: (1) spinal cord; (2) nerve roots; (3) covering or lining; and (4) fluid. Think of the spinal canal as a closed pipe filled with structures bathed in fluid.

NERVE ROOTS: The actual spinal cord runs from the brain down to about the lumbar area. About 2 dozen string-like structures called nerve roots hang below the spinal cord. Collectively they are called the cauda equina. These nerve roots can become damaged, inflamed, clumped together, or all three. Adhesions, internal scar tissue connecting tissues not normally connected, can cause clumping. When nerve roots get stuck to the arachnoid layer of the spinal canal cover, the term adhesive arachnoiditis is applied. If only inflammation, displacement, and clumping of nerve roots is seen on an MRI, the term “cauda equina syndrome” may be applied. Symptoms are similar to AA.

ARACHNOID: The cover or lining of the spinal cord is scientifically called the thecal sac or meninges. The inner layer is called the “Pia Mater”. It is extremely thin and fragile. The outer layer is the dura which is thick and firm. The arachnoid is the middle layer. It contains blood vessels and inflammatory cells and can become inflamed if irritated or damaged.

ARACHNOIDITIS: ARC is inflammation of the arachnoid layer of the spinal canal covering or lining which can be caused by trauma, infection, toxins, or friction between the covering and spinal cord or nerve roots. (ICD-10, G03.9) ARC most commonly develops in the lumbar spine area, but it also occurs in the cervical (neck) spine area.

ADHESIVE ARACHNOIDITIS (AA): This condition is present when there are adhesions between the arachnoid layer and the nerve roots in the cauda equina. Adhesions are seen on contrast magnetic resonance imaging (MRI). (ICD-10, G03.9)

TARLOV CYSTS: A cyst or outpouching of a spinal nerve root. (ICD-10, G96.19) They are often called “perineural” cysts. Tarlov cysts are frequently associated with ARC.

**ARC-Plain Arachnoiditis
AA-Adhesive Arachnoiditis**



ARACHNOIDITIS-NO LONGER RARE

TAKE AWAY FACT

If you have a common, chronic, spinal condition such as ruptured discs or scoliosis, and you live long enough, you may likely develop arachnoiditis.

The initiating cause of arachnoiditis may initially involve damage to nerve roots in the lumbar cauda equina or the arachnoid lining of the spinal canal. Arachnoiditis is simply inflammation of the lining, and adhesive arachnoiditis occurs when nerve roots of the cauda equina adhere to the lining by adhesions.

EXPLANATION

Damage to the nerve roots can be caused by:

1. FRICTION
2. COMPRESSION
3. TOXINS
4. TRAUMA
5. INFECTIONS

The nerve roots of the cauda equina are naturally suspended and float freely in spinal fluid which lubricates them just as oil does in your car's engine to prevent friction and corrosion. Spinal fluid also provides nourishment to the nerve roots and washes away toxins and biologic waste products of metabolism and inflammation. If nerve roots are forced to rub together or are compressed very long, inflammation will occur which may eventually form adhesions and cause attachment of the nerve roots to the arachnoid lining. When this occurs "adhesive arachnoiditis" is the result.

KEY FACTS TO KNOW

Chronic spinal conditions such as herniated or bulging discs, spinal canal narrowing (stenosis), malformations such as kyphoscoliosis, cysts (Tarlov or tumors), and degenerative arthritis may all produce friction or compression of the spinal nerve roots. Toxins including viruses, bacteria, dyes, and medicinal agents may enter the spinal canal and cause inflammation in nerve roots and/or the arachnoid lining.

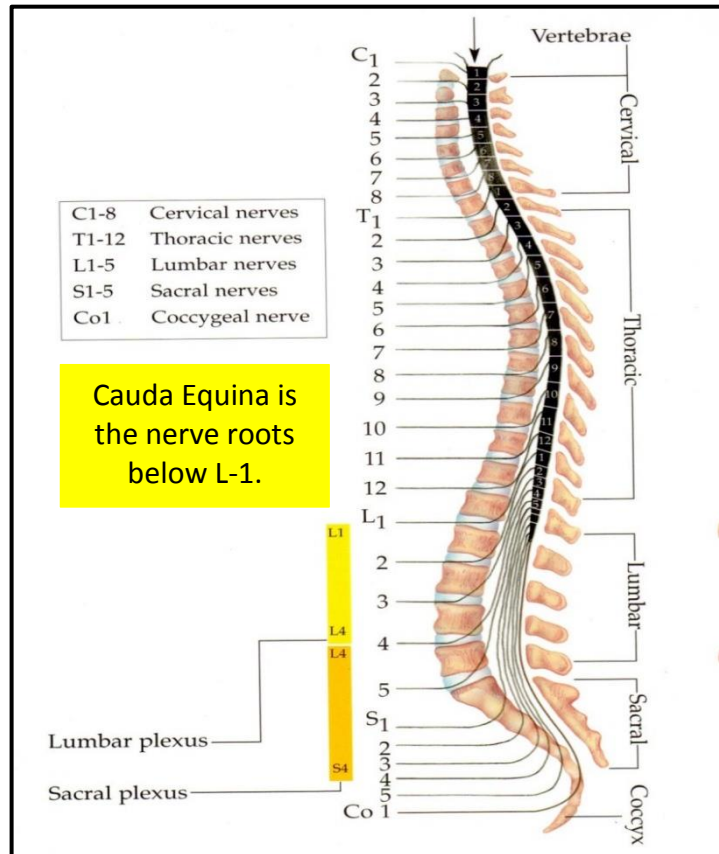
AGING POPULATION

Unfortunately, necessary medical procedures including surgery, epidural anesthesia, or spinal taps can inadvertently cause friction, compression, or the entry of toxins into the spinal canal. The population is aging and older persons commonly develop a spinal condition which can lead to arachnoiditis.

AA INVOLVES HANGING LUMBAR NERVE ROOTS

- Until recently arachnoiditis (ARC) was considered a rare disease. No more. Its incidence is up several hundred-fold this past decade. Most every community and medical practice now has cases.
- The technology of contrast MRI's has advanced so that ARC can be diagnosed in a person with typical history, symptoms, and physical exam.
- Treatment protocols have been recently developed thanks to new knowledge on neuroinflammation and neurogenesis.

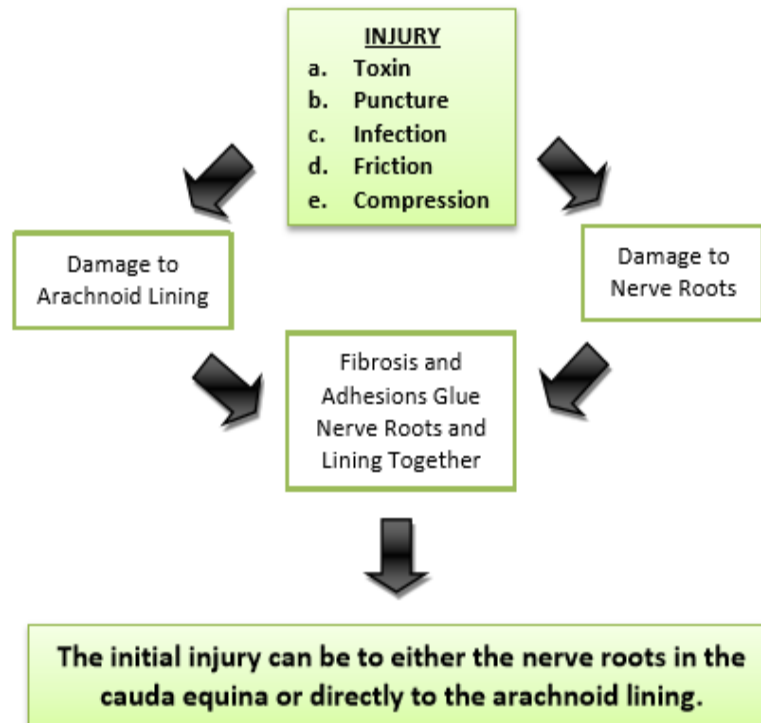
BOTTOM LINE
 There may be 1 to 2 million people in the United States with arachnoiditis as it is the root cause of severe pain in many patients that have severe lumbar and neck pain.




Arachnoiditis occurs when some nerve roots in the cauda equina adhere, by adhesion, to the spinal canal covering rather than float freely in spinal fluid.



TWO WAYS THAT ADHESIVE ARACHNOIDITIS MAY DEVELOP



A myth and old belief is that arachnoiditis only occurs when the spinal canal covering (arachnoid is the middle layer) is damaged by puncture or other insult.



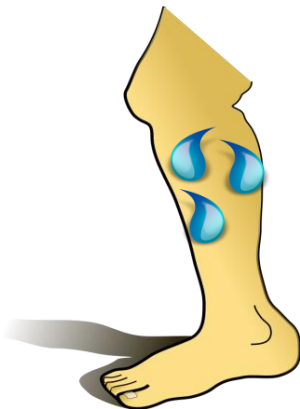
COMMON SYMPTOMS OF ADHESIVE ARACHNOIDITIS

There are many causes of back pain that may cause pain to go into the legs. Included are sprains, slipped discs, stenosis, arthritis, scoliosis, and Tarlov Cysts.

But which patients have arachnoiditis?

Arachnoiditis patients have a peculiar and unusual set of symptoms that are not usually present in other back pain patients.

- **Urinary Hesitancy, Poor Control**
- **Water Dripping on Legs**
- **Blurred Vision**
- **Headaches**
- **Pins and Needles in Legs**
- **Can't Stand or Sit Long in One Position**
- **Burning Feet**
- **Constipation/Diarrhea**
- **Pain Walking Stairs**
- **Weak Legs**



A goal of the Arachnoiditis Education Project is to insure that every medical practitioner and patient advocate including physicians, nurse practitioners, physicians assistants, chiropractors, and physical and massage therapists recognize a potential case and helps initiate the specialized treatment for AA.



DIAGNOSIS OF LUMBAR ADHESIVE ARACHNOIDITIS

THE DIAGNOSIS OF AA REQUIRES 4 STEPS OR COMPONENTS:

1. History and Symptoms
2. Physical Examination
3. Blood test for inflammatory markers
4. MRI with contrast

LABORATORY AND PHYSICAL SIGNS:

There is no specific laboratory test for AA, but some inflammatory markers such as C-reactive protein, erythrocyte sedimentation rate, or interleukins may elevate. There is also no specific physical sign for AA, but a back with indentation (sinking) or burnt skin ("scalded back") are seldom seen in diseases other than AA.

BIGGEST MISCONCEPTION:

An MRI, by itself, is not sufficient to make a diagnosis of AA. The MRI is ONLY to confirm the history, symptoms, and physical findings that are usual with AA.



DIAGNOSIS OF CERVICAL (NECK) ARACHNOIDITIS

The diagnosis of cervical (neck) AA is a physician's discretionary choice. Since the cervical spine does not have nerve roots, adhesions are rarely visible on a cervical MRI. The MRI is not as specific or as confirmatory as with lumbar AA and the physician must make a clinical diagnosis.

Adhesions are essentially not seen in modern day cervical ARC.

We have developed these criteria to make a clinical diagnosis of cervical neck ARC.

CRITERIA:

1. Severe pain which increases with forward flexing or backward extension of the neck.
2. History of trauma or disease involving the neck.
3. A contrast MRI that shows little or no passage of spinal fluid on one side of the spinal cord. (Spinal fluid obstruction occurs because the arachnoid lining thickens. This MRI finding may sometimes be called stenosis.)
4. Blood tests may show elevated inflammatory markers.
5. One or more arms show weakness, decreased reflexes, or diminished range of motion.

Cervical neck arachnoiditis is grossly underdiagnosed. Patients are routinely told that they have neck arthritis changes, degeneration, or cervical radiculopathy.

BIG PROBLEM: A delay in diagnosis and treatment must be avoided because arachnoiditis is an inflammation of the spinal canal lining, and it will usually progress and worsen without treatment.



SCREENING FOR LUMBAR ADHESIVE ARACHNOIDITIS

		YES	NO
1	Do you have constant back pain?		
2	Do you have difficulty starting or stopping urination?		
3	Do you have burning on the bottom of your feet?		
4	Do you have blurred vision or ringing in your ears?		
5	Do you have to stand after you have sat for 10 minutes?		
6	Have you had feelings of water dripping on your skin or bugs or worms crawling on your skin?		
7	Have you been diagnosed with Ehlers-Danlos Syndrome or Tarlov Cysts?		
8	Do you get full very fast and throw up food?		
If you answer yes to 5 of the 8, you very likely have adhesive arachnoiditis.			

Every health practitioner needs to be able to screen back pain patients for this disease.

WHY SCREEN FOR ARACHNOIDITIS?

**The earlier the diagnosis in the course of the disease,
the better the results of treatment.**



CONSEQUENCES AND COMPLICATIONS OF AA

✓ Spinal Fluid Flow Obstruction

- Headache
- Blurred vision
- Tinnitus (Ringing in the ears)
- Mental loss (bad memory, absent mindedness)

AA has some serious consequences and complications which may cause immense suffering, impairments, and shortened life span.

✓ Spinal Fluid Flow Leakage

- Contraction of paraspinal muscles
- Tissue over lumbar spine indents or “caves in”

✓ Sitting/Standing Ability Impaired

- Can't sit or stand in one position very long

✓ Autoimmune Systemic Manifestations

- Arthritis, fibromyalgia

✓ Neuropathic Symptoms

- Burning feet
- Allodynia (pain due to a stimulus that does not usually provoke pain)
- Hyperalgesia (increased pain from a stimulus that usually provokes pain)
- Mental loss (bad memory, absent mindedness)
- Dysautonomia (Bowel and Eating disruption)

✓ Severe Complications

- Paralysis
- Dementia
- Adrenal Failure
- Sepsis(Infection)



OUTCOMES OF UNTREATED ADHESIVE AA

THERE ARE 4 BASIC OUTCOMES WITH AA:

1. Total recovery
2. Progress stops but pain and some neurologic symptoms are permanent
3. Pain and neurologic impairments are intermittent (remissions and recurrences)
4. Worsening pain and neurologic impairments become constant

EXAMPLES OF IMPAIRMENT:

Bladder/Bowel Dysfunction
Sexual Dysfunction
Autoimmune Disorder
Paralysis
Dysautonomia

Dementia
Adrenal Failure
Sepsis
Death

We believe that we see either nerve repair or new nerve growth with certain hormone treatment, and we further believe that the remarkable improvement we see in many patients to be a result of neurogenesis (nerve growth).

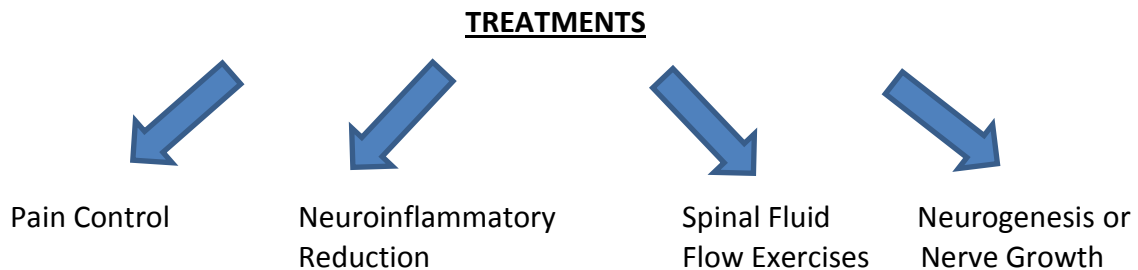
HOW DOES RECOVERY OCCUR?

When inflammation and adhesions form between the nerve roots and arachnoid layer, the diseased area is soft and amenable to resolution and recovery if the inflammation is successfully treated and suppressed. Unfortunately, the inflammation may form a scar and either trap and/or damage small nerve fibers which may cause pain and dysfunction of nerves that control such organs as the bladder and legs. Once a scar forms, we believe that small nerve fibers can grow around or through the scar and provide pain relief and improve nerve function.



TREATMENT – 4 BASIC COMPONENTS

Protocols have recently been developed for AA. We believe there are 4 essential components to effective treatment.



Each of the 4 components has some specialized measures for AA. Patients who do the best participate in all 4 components.

1. PAIN CONTROL – Effective agents must cross the blood brain barrier to control centralized and descending (brain discharge) pain. Not all agents currently in use do this.
2. NEUROINFLAMMATORY REDUCTION – Only a few agents cross the blood-brain barrier, enter the spinal fluid, and suppress a small cell called microglia which causes neuroinflammation.
3. SPINAL FLUID FLOW EXERCISES – AA will usually block some spinal fluid flow. Special simple exercises and plain-old walking will keep the flow going.
4. NEUROGENESIS (Nerve Growth) - There is the myth that the body can't grow new nerves or repair old ones.

The Arachnoiditis Education Project has actively followed and treated over 100 documented AA cases over the past two years. Our observation and recommendations are based on this experience, and future observations may bring different recommendations.



Arachnoiditis Bulletin 12

CHRONIC SPINAL FLUID LEAKAGE—NEW DISCOVERY ABOUT AA

We have learned that some AA patients chronically leak or “seep” spinal fluid into the tissues between the spine and skin over the lumbar spine area. The process is similar to a pipe that rusts and chronically leaks or “seeps” fluids out of the pipe. Unfortunately, the formation of inflammation between the nerve roots and arachnoid lining may cause microleaks through the entire spinal canal covering (dura).



HOW WAS THIS DISCOVERY MADE?: The Arachnoiditis Education Project has reviewed over 300 MRI’s cases of AA from around the world. Chronic spinal fluid leakage is evidenced by small amounts of contrast seen(?) in the soft tissues, muscles, and skin over the lumbar spine area. In addition, we have physically examined the backs of over 200 cases of documented AA patients.

In this discovery process we have learned that spinal fluid is toxic to muscle, subcutaneous fat, and skin. We believe that the body attempts to eliminate the spinal fluid by forming small, escape channels through the skin.

COMPLICATIONS OF CHRONIC SPINAL FLUID LEAKAGE: Over-time, these complications of leakage may occur:

1. Contracture of paraspinal muscles to the point that you can’t fully extend your arms or legs.
2. Chronic pain over the spine.
3. Abnormal, off-balance leaning.
4. Indentation (“caving in”) of tissues over the spine.

OUR INITIAL TREATMENT ATTEMPTS

1. Neuroinflammatory agents to stop leakage;
2. Stretching (range of motion) exercises to save back muscles;
3. Topical – massage – medications:
 - a. Pain and inflammation agents: lidocaine, homeopathic agents (Traumeel®, Zeel®)
 - b. Hormones: estradiol, medroxyprogesterone, prednisone
4. Electromagnetic and laser treatments

NOTE: This discovery and its treatments are in the very early stage and, hopefully, new and better information will be forthcoming.



Arachnoiditis Bulletin 13

MAJOR GOAL OF TREATMENT: STOP THE PROGRESSION

AA is a neuroinflammatory disease of nerve roots and the spinal canal covering or arachnoid layer. Neuroinflammation in the spinal canal has most of the same, basic characteristic as inflammation in joints of a patient with rheumatoid arthritis.

The neuroinflammation of the AA may take any of these paths:

1. Burn out leaving damage behind;
2. Go into remission and intermittently emerge with severe pain flares and more inflammation that causes further damage;
3. Cause progressive neurologic damage such as to involve the bladder, bowel, sex organs, or legs.

HERE IS THE TAKE HOME MESSAGE

If you have developed nerve root clumping and adhesion as seen on your MRI, you should plan on being on an indefinite, prevention program. If you choose to ignore possible progression and treatment, you can find yourself having sudden, without warning, neurologic impairments.



THE EARLIER THE TREATMENT—THE BETTER THE OUTCOME

Our observations in these bulletins come from treating and following over 100 chronic AA cases and reviewing over 300 MRI's and histories from an additional 300 documented cases. We have come to one KEY conclusion. The earlier treatment is started, the better the result or outcome.

WHY? Neuroinflammation causes adhesions to form between the lumbar nerve roots and the arachnoid lining or covering of the spinal canal. In the early stage of AA, adhesions and neuroinflammation can be resolved. After a time, however, neuroinflammation and adhesions not only cause permanent nerve damage, the area of neuroinflammation and adhesions cause clumping, scarring, and even calcification which is not resolvable.

EMERGENCY TREATMENT

Methylprednisolone (Medrol®) 6-day dose pak

PLUS

Ketorolac 30-60 mg, IM for 3 days

PLUS

Pregnenolone 50-100 mg for 5 days

Note: MRI evidence of nerve-root clumping or adhesions may not show for several weeks after the initiating cause. Emergency treatment may need to be done on purely, clinical grounds and suspicions.

WHEN AND WHAT IS AN EMERGENCY

Any patient, after a spinal tap or epidural injection, who develops severe back pain plus weak legs or urination difficulty, is a candidate for emergency/urgency treatment.

TAKE AWAY MESSAGE

If you or anyone you know may have AA, start treatment

ASAP!



WALKING IS AN ESSENTIAL MEASURE TO PREVENT PROGRESSION

WALK EVERY DAY

An AA patient **must take walks every day** to move spinal fluid and prevent adhesions.

Walk with toes pointed straight ahead. Swing your arms.

Lift your head so that your ears are directly over your shoulders. Breathe deeply.

PROPER SHOES

Persons with AA should wear supportive, tie shoes such as tennis shoes unless their feet are too painful. There are also some shoes designed to include copper or magnets in the soles.

Bare foot is better for an AA patient than is the modern-day practice of wearing thongs, sandals, flip flops, or slip-ons. These non-supportive footwear are a risk in 2 ways: (1) Falls; (2) prevents correct walking posture.

One slip, slide, or fall can set an AA patient back to square one. A fall may tear adhesions which may cause severe pain which then re-heal with more permanent, nerve entrapment impairments!

LIFTING AND BENDING

The AA patient must be very cautious and careful while lifting and bending over. If you attempt to lift something that weighs more than about 10 pounds, you run the risk of tearing adhesions or scars in and around your lower spinal canal. When you bend over, raise up slowly because a jerk or rapid movement can cause a tear or rip. If this happens, severe pain follows, and the damaged area may be worse than ever.

THE IMPORTANCE OF SPINE BRACING

Shockingly, few AA patients have been told they need to periodically wear a brace to protect their damaged area.

WORST SITUATION: Riding in a car on plane that has bucket seats.

DANGER SITUATION: Walking in unfamiliar areas such as a shopping center, grocery store, or social event.

**MOST IMPORTANT TIME TO
WEAR A BACK BRACE:**

PAIN FLARE



Arachnoiditis Bulletin 16

IMPROVING YOUR SPINAL FLUID FLOW

- ✓ AA commonly causes spinal fluid flow obstruction. When spinal fluid is obstructed you may get these symptoms among others:
 - Headache
 - Blurred vision
 - Inability to think or read
 - Weak legs
 - More pain
 - Poor balance
 - Ringing in ears

- ✓ Even worse—the spinal fluid cannot carry away inflammatory particles generated by the inflamed nerve roots. This retards healing. Another function of spinal fluid is to bring nutrients from your food to the nerve roots in the cauda equina. This function may also be impaired if spinal fluid flow is obstructed. You must do some of the following each day to keep spinal fluid flow moving.
 - Rock in a rocking chair
 - Walk on a trampoline
 - Use vibrator or massager over spine (Back scratchers and scrubbers are good)
 - Soak or wade in water
 - Walk and swing your arms (“Power Walking”)
 - Rock back and forth on your feet
 - Rub your spine with copper and/or a magnet
 - Nod your head up and down
 - Scrub your back with a brush
 - Deep breathing (diaphragm) with stomach



STRETCHING EXERCISES: STAY OUT OF THE WHEELCHAIR

FULL-BODY STRETCH LAYING DOWN: Lay down on the floor and do a full-body stretch. Count to 10.

FULL-BODY STRETCH STANDING: Spread hands and reach “to sky” until you feel pressure and tugging in your back. Count to 10.

SIT AND STRETCH ARMS: Stretch your arms and spread your fingers. Count to 10. Can do while sitting in a car or plane.

LEG RAISE WHILE LAYING DOWN: Raise leg until you feel tugging in your back. Count to 10.

LEG RAISE WHILE STANDING: Stabilize yourself next to a table or wall. Raise your leg and flex your foot.

KNEE PULL WHILE LAYING DOWN: Pull knee back until you feel tugging in your back. Count to 10.

HOW TO PREVENT CONTRACTURES OF YOUR ARMS AND LEGS

AA is primarily in the lumbar-sacral spinal canal. You may sustain some spinal fluid leakage. Between the neuroinflammation and leakage, AA patients frequently develop contractures of paraspinal muscles that involve your arms and legs. When this happens you can't extend your arms or legs to their full length. If you develop contractures between your legs and pelvis, you will end up in a walker or wheelchair.

CONTRACTURES: A PATIENT'S WORST ENEMY

A contracture is a scarring and shrinking of the muscles and tendons attached to your joints. Muscles are attached to your spine vertebrae, hips, and knees. When ARC starts to scar, shrink, and contract your muscles, you are pulled to one side and your hips and knees are pulled too tightly into their sockets. When contractures occur, more pain is generated. This leads to less reach and walking ability. The reason pain patients end up in a wheelchair or need a walker or cane is contractures. Given here is the basic stretching exercises which you must do daily if you have arachnoiditis.

STEPS FOR NECK ARC— DO 3 OR MORE TIMES A DAY!

1. Spread fingers.
2. Reach straight up with both arms until you feel pressure on your pain site. **DO NOT CAUSE PAIN!**
3. Hold for a count of 15.
4. Repeat at least 3 times a day.
5. Over time – try to extend your upward reach.



STRETCHING PRINCIPALS

1. Stretch to a point you feel tugging or pulling but not pain.
2. Standing is best to stretch but sitting or lying down is OK.
3. You should do more than raise your arms. Stretch your arms and legs in positions that let you know you are tugging or pulling on a contracted area.

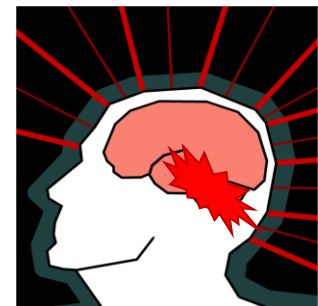THREE KINDS OF PAIN YOU MUST TACKLE

Almost all adhesive arachnoiditis (AA) patients develop centralized, intractable pain. A small cell in your brain and spinal cord called “microglia” activates and produces hot spots that are painful balls of electricity and neuroinflammation that operate 24/7.

Here’s the issue. If you have centralized, constant pain you will have to take steps to combat these 3 different kinds of pain:

	<u>PAIN TYPE</u>	<u>EXPLANATION OF THE 3 TYPES</u>
1.	Baseline	Always present in the hot spot of electricity and neuroinflammation
2.	Brain Discharge or Descending	The hot spot will periodically discharge electricity down your vagus and other nerves to give you such symptoms as jerking, burning, stabbing, water dripping, bugs crawling
3.	Flare	Episodes of severe, unexpected pain.

Centralized Pain



TREATMENT FOR EACH PAIN TYPE

<u>#1. BASELINE PAIN</u>		
<u>NEUROINFLAMMATION</u>	<u>SLEEP</u>	<u>NEUROGENENSIS (NERVE GROWTH)</u>
Ketorolac	Tryptophan	Pregnenolone
Methylprednisolone or dexamethasone	5-Hydroxytryptophan (5-HTP)	Human Chorionic Gonadotropin
Curcumin/Turmeric	Melatonin	Nandrolone
Serrapeptase		

<u>#2. BRAIN DISCHARGE OR DESCENDING PAIN</u>
Amphetamine Salts or Methylphenidate
Tizanidine or Clonidine
Taurine or Valerian Root

<u>#3. PAIN FLARES</u>
Oxytocin
Ketamine
Opioids – Last Resort